

Case Study: Seven year old girl with cerebral palsy, presenting with a dislocated left hip.

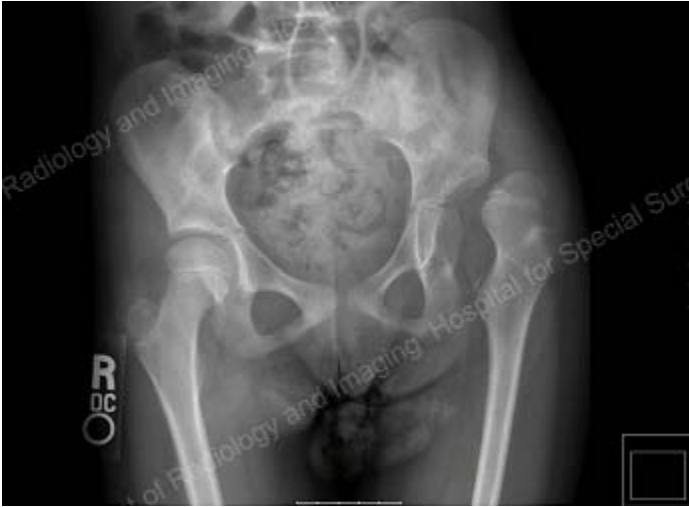

Fig. 1: AP x-ray demonstrating a dysplastic, dislocated left hip and coxa valga (abnormal alignment) of the right hip.

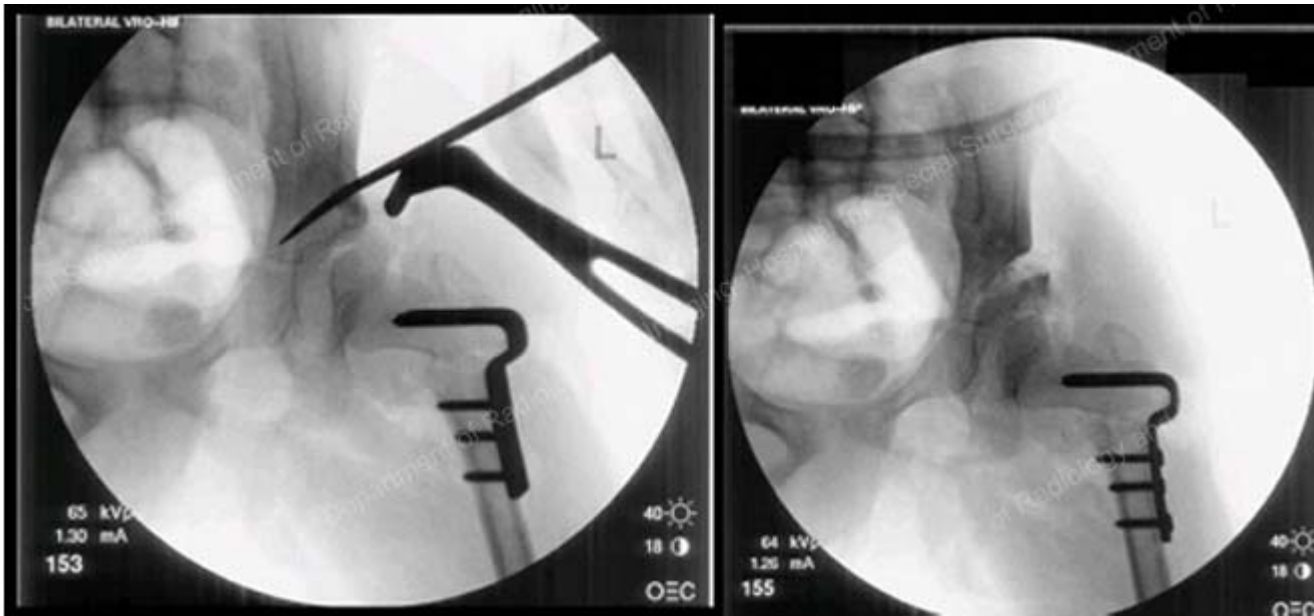


Fig. 2: Intraoperative x-ray images obtained during a left VRO (varus rotational osteotomy) and pelvic osteotomy.

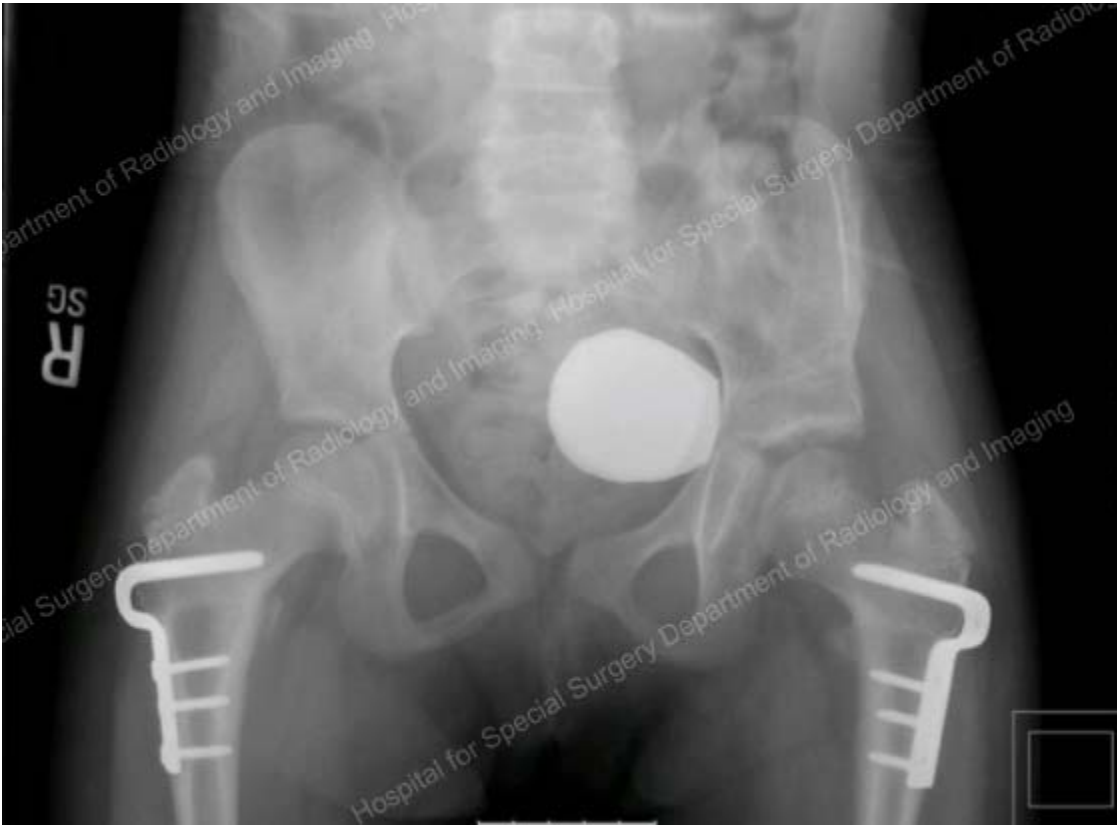

Fig. 3: Post operative AP x-ray obtained 1 year post left pelvic osteotomy and bilateral VRO demonstrating that both hips are located.